

A classification of pulmonary nodules by CT scan

M Bellomi

Department of Radiology, European Institute of Oncology, via Ripamonti 435, Milan, Italy

Correspondence to: Massimo Bellomi. Email: massimo.bellomi@ieo.it

Abstract

This Image Report aims to briefly describe, giving some imaging examples, the radiological definition of the features of lung nodules as commonly used by radiologists. We hope thus to improve communication and mutual understanding between radiologists and clinicians.

Published: 03/07/2012

Received: 12/06/2012

ecancer 2012, **6**:260 DOI: 10.3332/ecancer.2012.260

Copyright: © the authors; licensee ecancermedicalscience. This is an Open Access article distributed under the terms of the Creative Commons Attribution License (<http://creativecommons.org/licenses/by/3.0>), which permits unrestricted use, distribution, and reproduction in any medium, provided the original work is properly cited.

Introduction

A micronodule is a discrete, small, round, focal opacity in the lung parenchyma. Use of the term is most often limited to nodules with a diameter of less than 3 mm [1].

The majority of pulmonary nodules are asymptomatic and are detected by CT in the course of a lung cancer screening examination or as an occasional finding when performing a chest CT for other clinical problems.

Pulmonary nodules are classified as solid, partially solid, or non-solid (ground-glass opacities) [2].

Solid nodule

A solid nodule completely obscures the surrounding parenchyma; it has homogenous soft-tissue attenuation and well-defined margins with normal parenchyma.

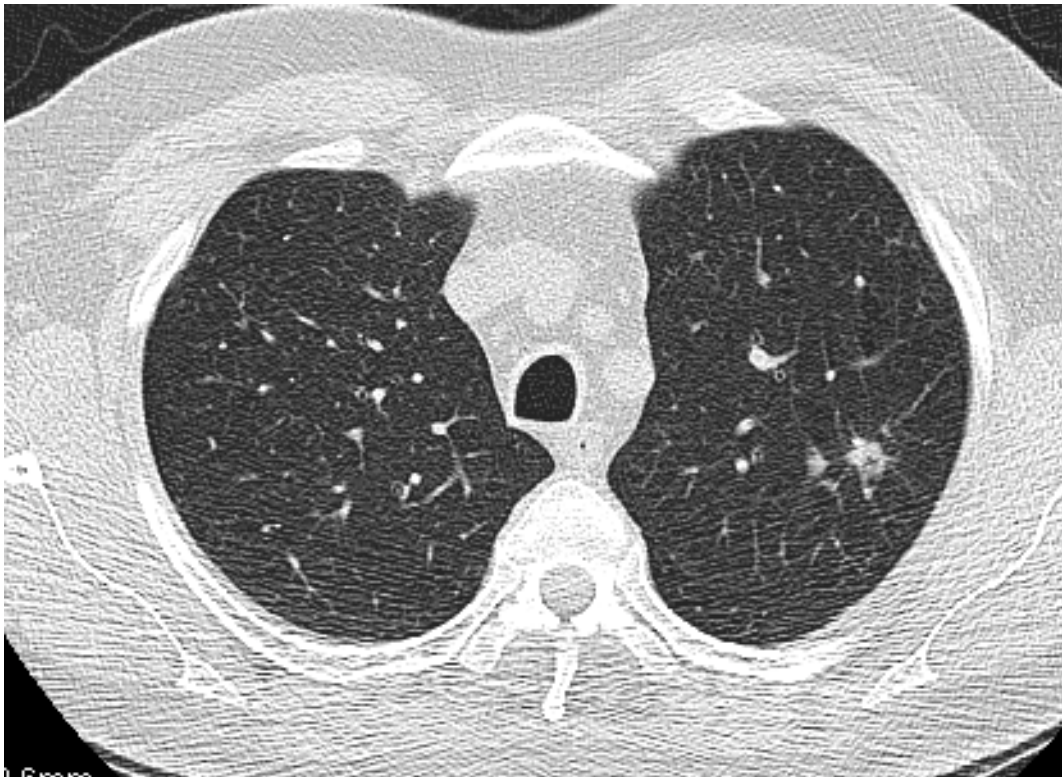


Figure 1: A solid nodule in the upper left lobe with irregular margins. This is a T1 adenocarcinoma of the lung.

Solid nodule with well-defined margins

This is a solid nodule with homogenous soft-tissue attenuation and well-defined margins with normal parenchyma.

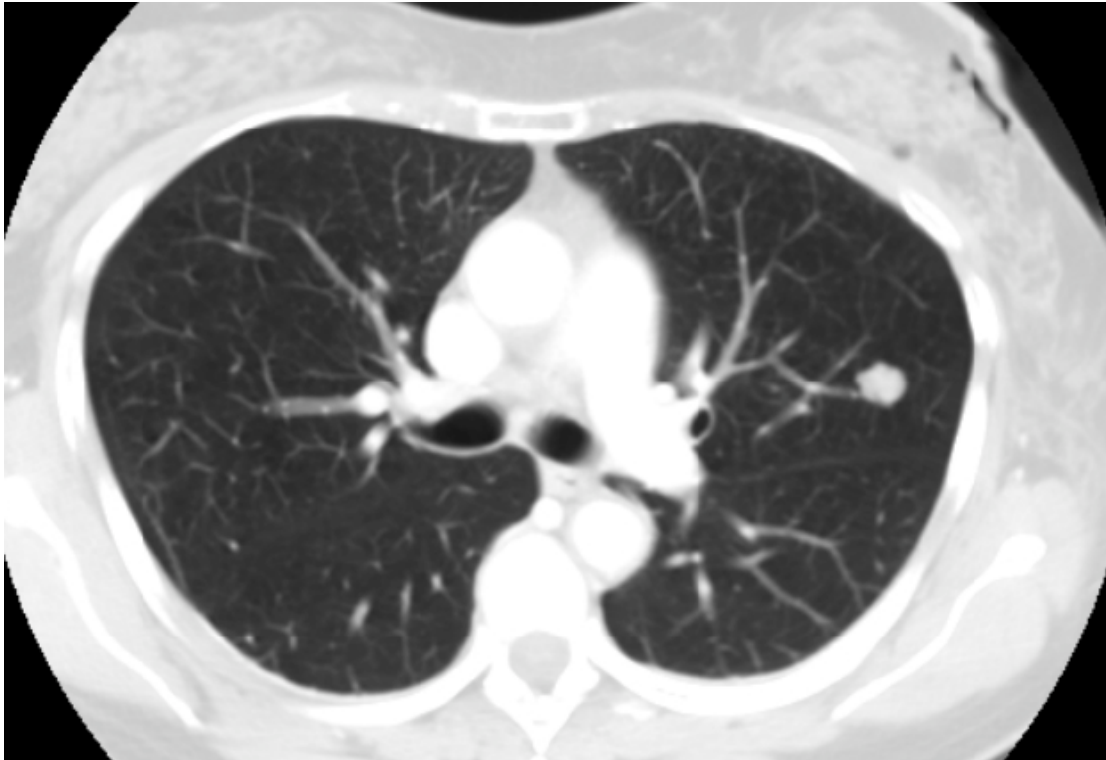


Figure 2: A solid nodule in the upper left lobe with regular, well-defined margins. This is a lung amartoma.

Semisolid nodule

This is a semisolid nodule consisting of both ground-glass and solid soft-tissue attenuation components. It partially obscures the surrounding parenchyma.

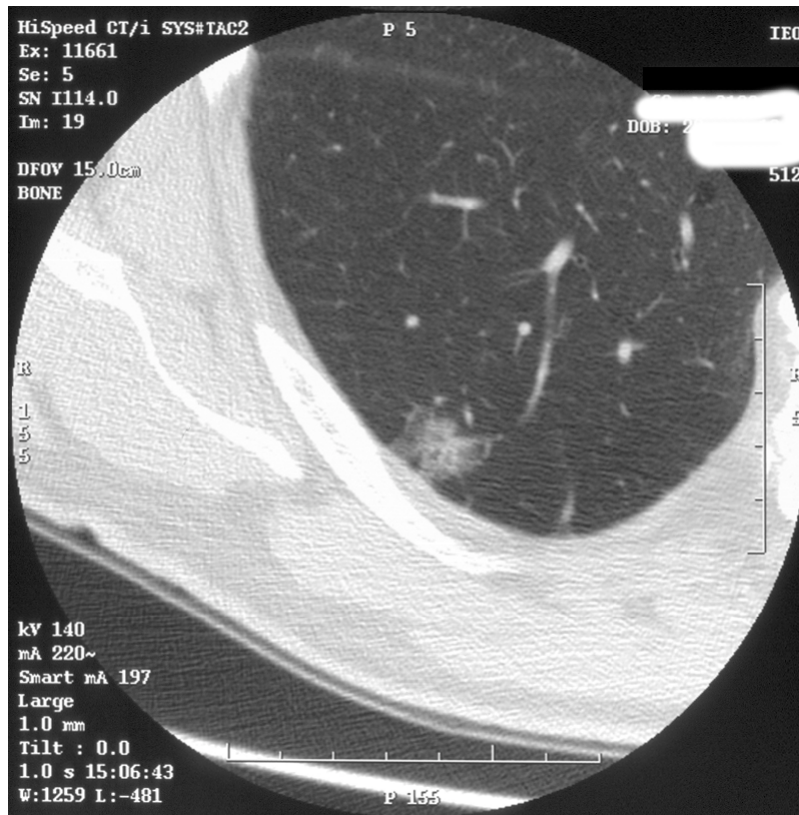

Figure 3: A semisolid nodule in the lower right lobe. This is an adenocarcinoma with a bronchioloalveolar component.

Ground-glass nodule (synonym, non-solid nodule)

These manifest as an area of hazy increased attenuation that does not obliterate the bronchial and vascular margins. They can be due to inflammatory changes, benign lesions, or carcinoma (often bronchioloalveolar).

They are most difficult to interpret for radiologists [3].

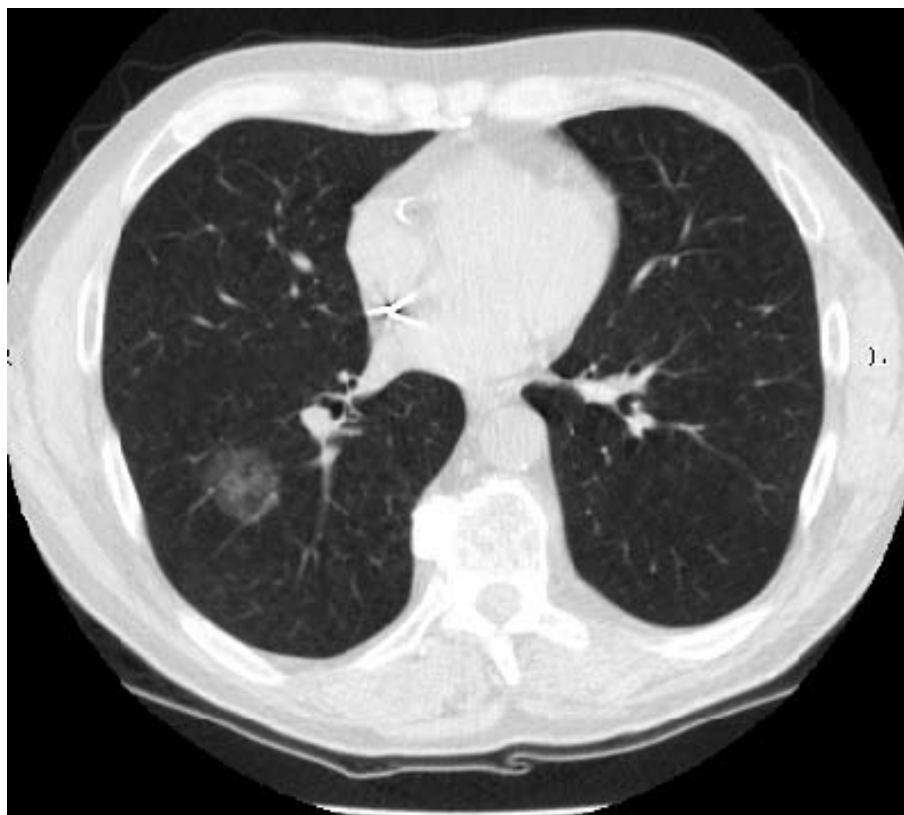

Figure 4: This is a non-small-cell lung cancer.

References

1. Hansell DM *et al* (2008) **Fleischner society: glossary of terms for thoracic imaging** *Radiology* 3 697–722 DOI: [10.1148/radiol.2462070712](https://doi.org/10.1148/radiol.2462070712)
2. Henschke CI *et al* (2002) **CT screening for lung cancer: frequency and significance of part solid and nonsolid nodules** *AJR Am J Roentgenol* 178 1053–1057 PMID: [11959700](https://pubmed.ncbi.nlm.nih.gov/11959700/)
3. Kim HY *et al* (2007) **Persistent pulmonary nodular ground-glass opacity at thin-section CT: histopathologic comparisons** *Radiology* 245 (1) 267–275 DOI: [10.1148/radiol.2451061682](https://doi.org/10.1148/radiol.2451061682) PMID: [17885195](https://pubmed.ncbi.nlm.nih.gov/17885195/)